Real-Time Elastography for Distinguishing Angiomyolipoma From Renal Cell Carcinoma: Preliminary Observations

Sinan Tan[1]
Muhammed Fuat Özcan[2]
Fatih Tezcan[1]
Serdar Balcı[3]
Mustafa Karaoğlanoğlu[1]
Bülent Huddam[4]
Halil Arslan[1]

AJR 2013; 200:W369–W375

Paula Pinto2013

ELASTOGRAFIA

Real-time elastography is a newly introduced sonographic technique to assess tissue elasticity (the degree of tissue hardness or softness) in real time, by overlay of a color map on top of the gray-scale (B-mode) image [1].

A ecografia modo B associada à elastografia é uma técnica que permite avaliar a maior ou menor elasticidade/dureza dos tecidos em tempo real sobrepondo um mapa de côr na imagem em modoB

Objetivamente, pode ser utilizada na prática clínica para diferenciar diferentes tipos de tecidos (mama,fígado,próstata,tiróide…)

CLÍNICA UNIVERSITÁRIA DE IMAGIOLOGIA
HOSPITAIS DA UNIVERSIDADE DE COIMBRA

CLÍNICA UNIVERSITÁRIA DE IMAGIOLOGIA
HOSPITAIS DA UNIVERSIDADE DE COIMBRA

OBJECTIVE. The objective of this study was to determine the diagnostic performance of sonoelastography for differentiating angiomyolipomas from renal cell carcinomas.

Objectivo: avaliar prospetivamente a capacidade diagnóstica da elastografia na diferenciação de angiomiolipomas/Tumor células renais

MATERIAL E MÉTODOS

Subjects and Methods

- 47 pacientes - 32(M);15(H)
- Idades-24-79anos
- Massas renais -19(tcr) ; 28(aml)
- Sonoelastografia - 2 Radiologistas
- Logiq E9 GE Healthcare
- Sonda convexa 2,8-5MHz
- Paciente posição supina/dec.lateral
- Fator de compressão (5-7)

CLÍNICA UNIVERSITÁRIA DE IMAGIOLOGIA
HOSPITAIS DA UNIVERSIDADE DE COIMBRA

CLÍNICA UNIVERSITÁRIA DE IMAGIOLOGIA
HOSPITAIS DA UNIVERSIDADE DE COIMBRA

TABLE 1: Description of Elastography Patterns

Elasticity Pattern	Description
Type 1	Lesion is completely soft (mixture of green, yellow, and red), without areas of no strain (blue)
Type 2	Lesion is predominantly soft, with some areas of no strain (blue), representing < 50% of the tumor area
Type 3	Lesion is predominantly stiff, but soft areas are still present; areas of no strain (blue) are present in ≥ 50% of the tumor area
Type 4	Lesion is completely stiff (ranging from light blue to dark blue)

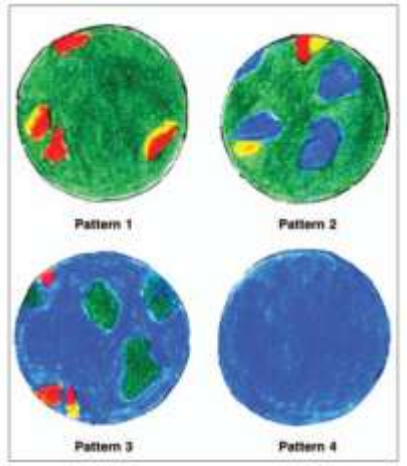

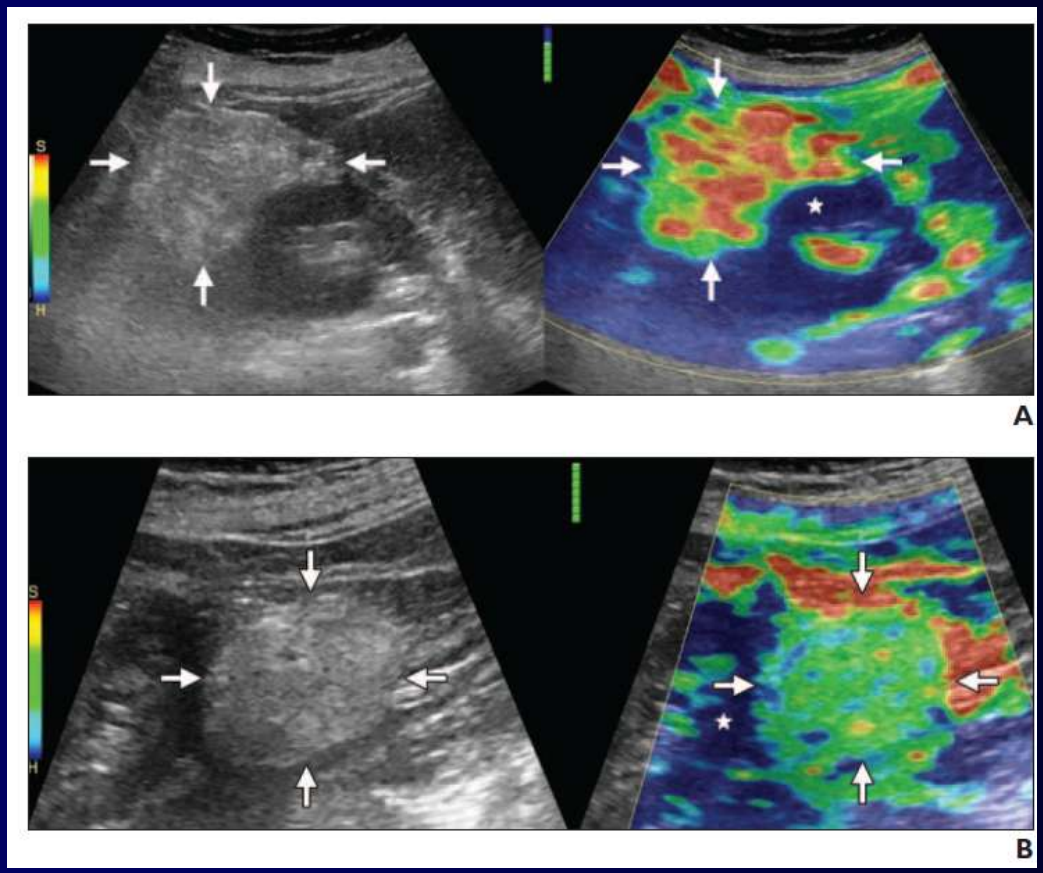

A, Angiomyolipoma (*arrows*) with type 1 elasticity pattern in 35-year-old woman. Star denotes renal cortex.
B, Angiomyolipoma (*arrows*) with type 2 elasticity pattern in 39-year-old woman. Star denotes renal cortex.

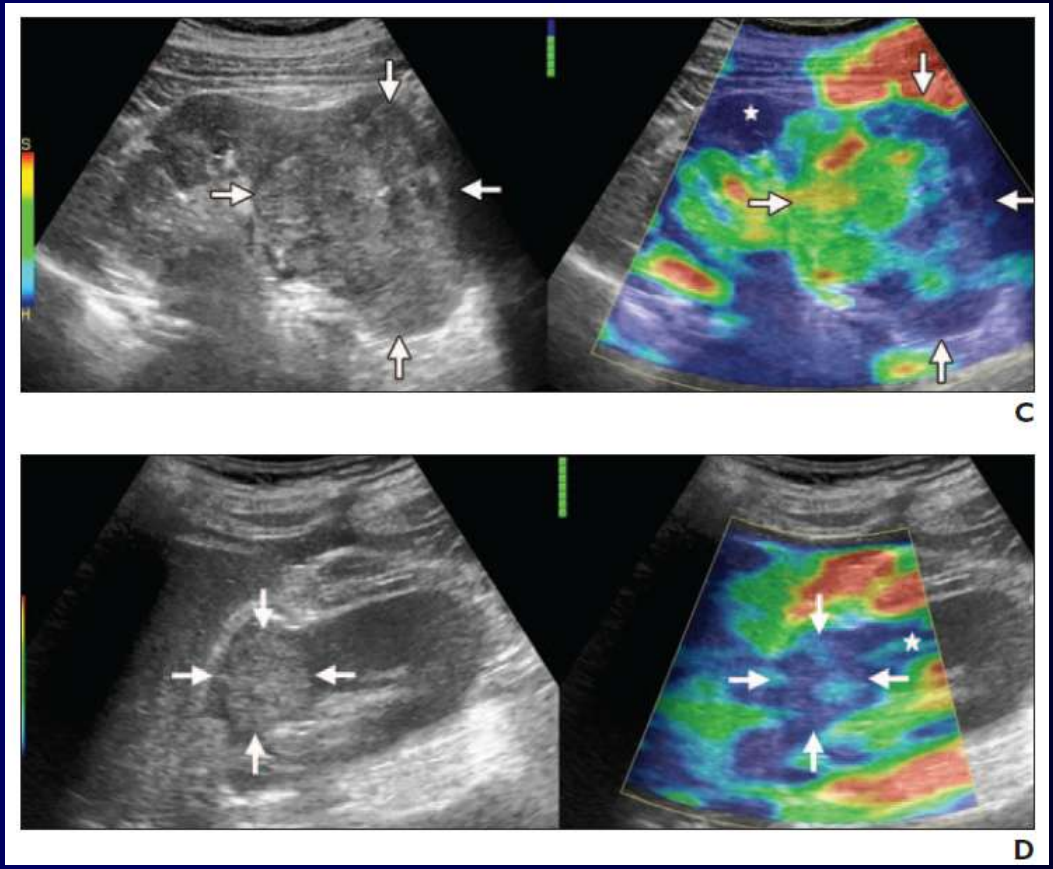

C, Clear cell renal cell carcinoma (*arrows*) with type 3 elasticity pattern in 60-year-old man. Star denotes renal cortex.
D, Clear cell renal cell carcinoma (*arrows*) with type 4 elasiticity pattern in 57-year-old man. Star denotes renal cortex.

The strain ratio for all renal lesions was measured by comparing the tumor (B) to the adjacent normal renal cortex (A). The first region of interest (ROI) was placed in the renal cortex at a depth the same or as close as possible to the depth of the tumor (Fig. 4). Next, the second ROI was manually drawn around the margin of the tumor [20]. The strain ratio (B/A) reflecting the property of stiffness of the lesion was then automatically calculated on the sonography machine.

Strain ratio (B/A):

- compara lesão com cortex renal normal adjacente
- B/A – relação de dureza (automaticamente calculada pelo ecógrafo)
- Reflete a propriedade de dureza

CLÍNICA UNIVERSITÁRIA DE IMAGIOLOGIA
HOSPITAIS DA UNIVERSIDADE DE COIMBRA

Results

- Diferenças estatisticamente significativas nos padrões de elasticidade ($p<0,001$)
- Útil na distinção de TCR/AML-cutoff – 0,3

CLÍNICA UNIVERSITÁRIA DE IMAGIOLOGIA
HOSPITAIS DA UNIVERSIDADE DE COIMBRA

CLÍNICA UNIVERSITÁRIA DE IMAGIOLOGIA
HOSPITAIS DA UNIVERSIDADE DE COIMBRA

CONCLUSION. Our results show that real-time elastography may be useful in differentiating angiomyolipomas from renal cell carcinomas, by use of both elasticity patterns and strain ratios.

Elastografia em tempo real pode ser útil na diferenciação TCR/AML

CLÍNICA UNIVERSITÁRIA DE IMAGIOLOGIA
HOSPITAIS DA UNIVERSIDADE DE COIMBRA

Limitações:

- Pressão aplicada/operador
- Valores de elasticidade variam com diferentes graus de c. manual
- Lesões quísticas puras
- Variáveis - tamanho, profundidade, densidade podem afectar resultados

"Virtual Touch" (ARFI – Siemens)